

## The effect of Oleuropein on liver in experimental allergic rhinitis model

Role of Oleuropein in systemic allergy

Özlem Öztöpez<sup>1</sup>, Özlem Coşkun<sup>1</sup>, Başak Büyük<sup>2</sup>

<sup>1</sup>Department of Biophysics, Faculty of Medicine, Çanakkale Onsekiz Mart University, Çanakkale

<sup>2</sup>Department of Histology-Embryology, Faculty of Medicine, İzmir Democracy University, İzmir, Turkey

### Abstract

**Aim:** The aim of this study is to investigate the supplemental effect of oleuropein which is the most commonly used corticosteroid in AR (Allergic rhinitis) treatment and to evaluate possible inflammatory-reducing properties in the liver.

**Material and Methods:** The study was carried out on 42 male Wistar rats. The animals were randomly divided into 6 groups including G1 (C), G2 (AR), G3 (AR+SF), G4 (AR+MF), G5 (AR+OLE), G6 (AR+OLE+MF). Tumor necrosis factor-alpha (TNF- $\alpha$ ) and Interleukin-1 beta (IL-1 $\beta$ ) gene expression levels were assessed by RT-PCR analysis in liver tissues. In addition, liver tissues were evaluated histopathologically as a result of hematoxylin eosin (H&E) staining.

**Results:** TNF- $\alpha$  and IL-1 $\beta$  gene expression levels in liver tissues were compared between groups and the results were statistically significant in all groups ( $p < 0.000$ ). Histopathological evaluation in H&E sections, sinusoidal dilatation, and hydropic degeneration were not observed in the liver tissue architecture of G1 (C). As a result of the examination of the sections belonging to G2 (AR), the location of hepatocyte cords and minimal destruction in portal areas were observed in organ architecture, and intensive sinusoidal dilatation was observed. Sinusoidal dilatation was advanced in G3 (AR+SF). In addition, swelling and moderate hydropic degeneration were observed in hepatocytes, and focal lytic necrosis areas were not observed in G3 (AR+SF). All groups in terms of sinusoidal dilatation and hydropic degeneration were significant differences statistically ( $p = 0.000; 0.001$ ).

**Discussion:** The present data indicated that oleuropein treatment suppresses inflammation in liver tissue caused by AR and it has no side effect in the experimental AR model. Oleuropein can be used as an auxiliary agent in the treatment of routine AR.

### Keywords

Allergic rhinitis; Steroid; Oleuropein; Inflammation; Rat

DOI: 10.4328/ACAM.20135 Received: 2020-02-12 Accepted: 2020-02-21 Published Online: 2020-03-02 Printed: 2020-04-01 Ann Clin Anal Med 2020;11(Suppl 1): S61-66

Corresponding Author: Özlem Öztöpez, Department of Biophysics, Faculty of Medicine, Çanakkale Onsekiz Mart University, Çanakkale, Turkey.

E-mail: ozlemoztopuz@yahoo.com.tr GSM: +90 5325851112

Corresponding Author ORCID ID: <https://orcid.org/0000-0002-1373-6311>

## Introduction

Allergic rhinitis (AR) is a chronic upper respiratory tract disease characterized by congestion, rhinorrhea, itching, sneezing and postnasal drip, which occurs with inflammation in the nasal mucosa. For the occurrence of AR, it is necessary to be exposed to any allergen and be immunologically sensitive to this allergen. Today, topical and oral antihistamines, topical and oral corticosteroids, topical and oral decongestants, mast cell stabilizers, mucolytics, anticholinergic agents, anti-IgE antibody therapies and saline sprays are used in AR treatment [1,2]. However, these drugs can also have serious side effects. AR models have been developed on various animals in order to explain the pathophysiology of AR disease and to find alternative active substances that can be used in the treatment [3]. Animal models of allergic diseases make serious contributions to understand the pathogenesis at the immunological, physiological and histopathological level, and to add new information to the current literature in prevention and treatment [3].

Oleuropein is an active component of olive leaf and has various pharmacological activities such as hepatoprotective, cardioprotective, antioxidant, anti-inflammatory, anti-cancer, anti-atherogenic activity, anti-microbial properties and neuroprotective effect [4].

In recent years, new predictive biomarkers, diagnostic tools, and therapeutic opportunities have been created for the better elucidation of inflammatory mechanisms in allergic diseases such as AR and asthma [5]. In the treatment of AR, it is necessary to avoid side effects that may occur while controlling the symptoms. The most effective anti-inflammatory drug is corticosteroids. If they are given systemically, they control all symptoms, but many harmful side effects also occur. For this reason, systemic steroids should not be used in the treatment of AR [6]. Intranasal corticosteroids are the most effective anti-inflammatory drug to control all symptoms, including nasal congestion, in the treatment of AR. They perform their effects by preventing vasoconstriction, decreased mucosal edema, suppression of cytokine production, and migration of inflammatory cells [7].

Biotransformation of the liver is an important process in terms of detoxification of endogenous and exogenous harmful substances. Steroids, vaccines, and antiviral drugs used to treat many diseases, at the same time cause adverse effects when administered for a long time [8]. Therefore, there is a need for hepatoprotective agents that have anti-inflammatory activity. Cytokines are polypeptide and the most important ones in inflammation are interleukins (IL) and tumor necrosis factor-alpha (TNF- $\alpha$ ). In particular, IL-1 and TNF- $\alpha$  share many common biological properties. Both are created by activated macrophages, lymphocytes, and other cell types and are called pro-inflammatory cytokines. They have a triggering effect on systemic acute phase reactions [9]. The family of proinflammatory cytokines IL-1 represents a group of proteins with synergistic biological responses. IL-1 $\alpha$  and IL-1 $\beta$  and their precursor forms play an important role in increasing inflammation and host defense. Examination of these proteins in many diseases, including allergic diseases, provided a better understanding of the underlying general inflammation

associated with these syndromes. It has been found that IL-1 plays an important role in nasal fluid before and after the allergen threat, especially in people with AR [10].

The aim of our study is to investigate the effect of mometasone furoate (MF) which is one of the most frequently used intranasal steroid active substance and oleuropein in allergen (aluminum hydroxide and ovalbumin) induced AR rats. For this purpose, the gene expression profile of TNF- $\alpha$  and IL-1 from the proinflammatory cytokine family will be examined. In addition, histopathological changes in liver tissue will be evaluated.

## Material and Methods

### Chemicals

Ovalbumin (OVA) was purchased from Sigma-Aldrich (Cat no: A-5503-1), Mometasone furoate (MF) (Nasonex) was purchased from Merck Istanbul, Turkey.

### Olive leaf extract (OLE) preparation

OLE preparation was made in Çanakkale Onsekiz Mart University, Faculty of Engineering, Food Engineering Department Laboratories.

Olive leaves were harvested from olive tree (*Olea europaea*) variety Ladolia grown in Gökçeada (Imbros), Çanakkale, Turkey. Leaves were dried at 80 °C for 4 h. Dried leaves were ground using Delonghi coffee grinder KG49 and then, filtered using 850 mm laboratory sieve. Olive leaf powder was extracted 1:5 (w:v) with hot water in water bath (Memmert WNB 10, Germany) at 80 °C for 10 min. The mixture was filtered using cotton fabric and transferred to falcon tubes (15 mL). Olive leaf extracts (OLE) were stored at -20 °C to prevent degradation of oleuropein during the experiment.

### Animal model

A total of 42 male rats with a weight of 200-300 gr in Wistar Albino type from ÇOMUDAM were used in the study. The animals were maintained under standard housing conditions (22°C room temperature and 12-hour light/dark cycle) and supplied with standard rodent chow and tap water ad libitum. All animal procedures were approved by the Çanakkale 18 Mart University Institutional Animal Care and Use Committee (Protocol number: 2017/08-11 and date:25.08.2017).

### Experimental design

Forty-two rats were randomly assigned to six groups.

Group 1 (C): Control group was fed with tap water and standard chow (n=7).

Group 2 (AR): 1 mg OVA and 10 mg of aluminum hydroxide were given intraperitoneally to rats at the same time every day for 14 days. In addition, in order to increase allergy for 7 days, 10  $\mu$ g/ $\mu$ l OVA was given to each nostril with micropipette, and after the intranasal OVA repeated after intraperitoneal OVA, nasal examination was performed with observation. Nasal symptom scores were independently evaluated by two blind observers to experimental groups (Nasal symptoms such as sneezing, itching, and discharge were rated on a 0-3 score scale) (n=7).

Group 3 (AR+SF): After AR model was established in rats, saline (SF) was given intraperitoneally at the same time every day for 14 days (n=7).

Group 4 (AR+MF): After the AR model was established in rats, 0.1 ml of MF (steroid) was applied to each nostril using a micropipette for 14 days (n=7).

Group 5 (AR+OLE): After the AR model was established in rats, oleuropein 20 mg/kg extract was diluted in 0.1 ml SF and was applied to each nostril using a micropipette for 14 days (n=7).

Group 6 (AR+OLE+MF): After the AR model was established in rats, oleuropein 20 mg/kg extract was diluted in 0.1 ml SF and 0.1 ml of MF (steroid) were applied to each nostril using a micropipette for 14 days (n=7).

Doses are adjusted by reference [11].

On the fourteenth day of the study, rats were anesthetized with 5 mg/kg xylazine (Rompun®, Bayer, Istanbul, Turkey) and 50 mg/kg ketamine hydrochloride (Ketalar®, Eczacibasi, Istanbul, Turkey). Blood samples were drawn by cardiac puncture under anesthesia conditions. After sacrifice, rat livers were immediately harvested for genetic and histological examination in all groups.

**Gene expression analysis (RT-PCR)**

Total ribonucleic acid (RNA) was isolated from 10-30 mg liver tissue using a QIAamp RNA spin column (PureLink RNA MiniKit, Ambion). The quality and amount of the RNA were examined by determining 260/280 absorbance ratio using a NanoDrop ND-1000 Spectrophotometer. Reverse transcription was performed using a kit (High Capacity cDNA Reverse Transcription Kit). All samples were amplified using Taqmanprob PCR master mix (Applied Biosystems). Synthesized complementary (cDNA) samples were used for quantitative real-time polymerase chain reaction (PCR, ABI Stepone). Gene expression levels were analyzed by qRT-PCR using Applied Biosystems™ TaqMan® Gene Expression Assays (Thermo Fisher Scientific, U.S.). Beta-actin was used for the normalization of the genes. Primer ID numbers for TNF-α, IL-1β and β-actin are Rn01525859\_g1, Rn00580432\_m1, and Rn00667869\_m1, respectively (Thermo Fisher).

**Histopathological examinations**

After fixation, dehydration, and clearing, liver tissues were embedded in paraffin. Paraffin blocks were cut 5 mm thick on Rotatory Microtome (Leica RM2125 RTS) and hematoxylin-eosin (H&E) staining was performed. The presence of hydropic degeneration, sinusoidal dilatation in histopathological sections was examined under a light microscope (Zeiss Axio Scope A1) and was graded on a 0-3 semi-quantitative scale as follows. Groups were examined for hydropic degeneration and sinusoidal dilatation and histopathological damage score was calculated. 0: no damage, 1: slight damage, 2: moderate damage, 3: severe damage

**Statistical analysis**

The SPSS (Statistical Packages of Social Sciences, SPSS for Windows, Version 20.0, Chicago, IC, USA) was utilized for data analysis. Mean, standard error, standard deviation, median, minimum and maximum values, were used to present the descriptive data. To analyze the gene expression data, the parametric One-Way ANOVA followed by the Tukey were used. The non-parametric Kruskal Wallis Variance Analysis test followed by the Dum-Bonferroni correction was made for pairwise comparisons for histopathological results. p<0.05 value was considered statistically significant.

**Results**

**TNF-α, IL-1β Gene Expression Level**

TNF-α and IL-1β gene expression levels in liver tissues were compared between groups, TNF-α and IL-1β values were statistically significant (p<0.000).

TNF-α and IL-1β gene expression levels were significantly increased in the G2 (AR) compared to the other groups. TNF-α and IL-1β gene expression levels were significantly reduced in the G4 (AR+MF) compared to other groups (p <0.000). MF and OLE were given in the G6 (AR+OLE+MF); TNF-α and IL-1β gene expression levels were decreased compared to G1(C) and G4 (AR+MF).

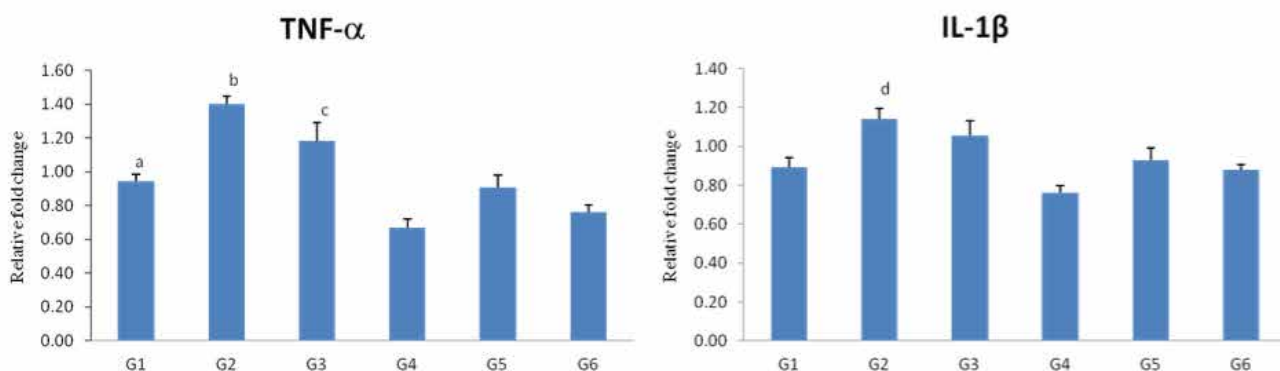
**Histopathological Findings**

As a result of histopathological evaluation in H&E sections, sinusoidal dilatation and hydropic degeneration were not observed in the liver tissue architecture of G1 (C) (Table 1, Figure 2). As a result of the examination of the sections belonging to G2 (AR), in the location of hepatocyte cords, minimal destruction in portal areas, intensive sinusoidal dilatation were observed. Sinusoidal dilatation was advanced in G3 (AR+SF). In addition, swelling and moderate hydropic degeneration were observed in hepatocytes, and focal lytic necrosis areas were not observed in G3 (AR+SF) (Figures 2 and 3). When sinusoidal dilatation was compared between groups, it was found statistically significant between G1 (C) and G3 (AR+SF), G1(C) and G4 (AR+MF), G1 (C) and G2 (AR) respectively (p=0.001; 0.001; 0.000). In comparison of hydropic degeneration, a statistically significant difference was found between G1 (C) and G2 (AR), G1 (C) and G6 (AR + MF + OLE) (p=0.000; 0.044). There were significant differences between the groups in terms of sinusoidal dilatation and hydropic degeneration (p=0.000;0.001). In G4 (AR+MF), G5 (AR+OLE) and G6 (AR+MF+OLE) sections, sinusoidal dilatation areas were observed to be significantly reduced compared to G2 (AR). The microscopic image of G5 (AR+OLE) was similar to that of the G1 (C) (Figure 2).

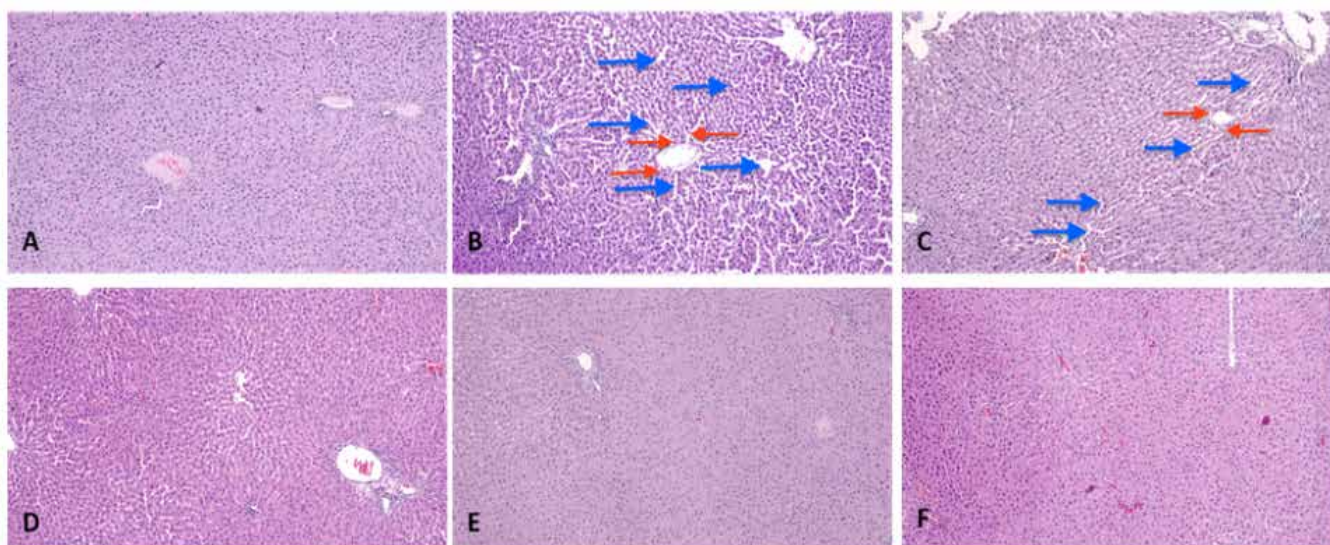
**Table 1.** Comparison of histopathological parameters of the groups

Groups		Sinusoidal dilatation	Hydropic degeneration
G1 (C) (n=7)	mean±sd	0.0	0.0
	median (min-max)	(0.0-0.0) 0.0±0.0	(0.0-0.0) 0.0±0.0
G2 (AR) (n=7)	mean±sd	1.9±0.6	2.1±0.8
	median (min-max)	2.0 (1.0-3.0)	2.0 (1.0-3.0)
G3 (AR+SF) (n=7)	mean±sd	1.4±0.5	1.1±0.8
	median (min-max)	1.0 (1.0-2.0)	1.0 (1.0-2.0)
G4 (AR+MF) (n=7)	mean±sd	1.4±0.7	1.1±0.6
	median (min-max)	1.5 (0.0-2.0)	1.0 (0.0-2.0)
G5 (AR+OLE) (n=7)	mean±sd	1.0±0.7	1.1±0.9
	median (min-max)	1.0 (0.0-2.0)	1.0 (0.0-3.0)
G6 (AR+MF+OLE) (n=7)	mean±sd	1.1±0.8	1.4±1.0
	median (min-max)	1.0 (0.0-3.0)	1.0 (0.0-3.0)
p		0.000	0.001

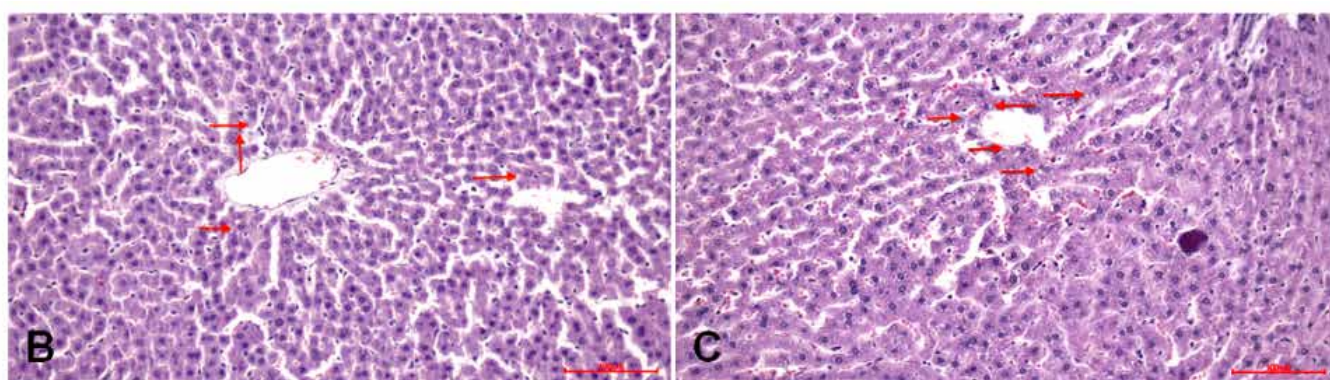
sd: standard deviation p: Kruskal Wallis Variance Analysis test followed by Dum-Bonferroni correction, p<0.05



**Figure 1.** Changes in TNF- $\alpha$ , IL-1 $\beta$  gene expression levels between groups. To evaluate the expression levels of the genes, the  $2^{-\Delta\Delta Ct}$  method was used after normalization of expression levels against  $\beta$ -actin mRNA level [ $2^{-\Delta\Delta Ct} = (Ct \text{ target gene} - Ct \text{ reference gene})$ ]. a: compared to G2 (AR) and G4 (AR+MF), b and c: compared to G4 (AR+MF), G5 (AR+OLE), G6 (AR+MF+OLE), d: compared to all groups  $p < 0.05$ .



**Figure 2.** Light microscopic images of G1 (C), G2 (AR), G3 (AR+SF), G4 (AR+MF), G5 (AR+OLE) and G6 (AR+MF+OLE) are given in A, B, C, D, E and F panel, respectively. Blue arrows indicate sinusoidal dilation areas, while red arrows indicate hydropic degeneration (Magnification x100). Sinusoidal dilation and hydropic degeneration findings were scored as follows: 0: no damage, 1: mild damage, 2: moderate damage, 3: serious damage.



**Figure 3.** The microscopic section of hydropic degeneration in liver tissues of G2 (AR) and G3 (AR+SF) is indicated by red arrows on panels B and C, respectively (Magnification x200).



## Discussion

AR is a common disease characterized by T-helper (Th) 2-mediated inflammation through hypersensitivity from seasonal or environmental allergens [12]. Therefore, allergic inflammation is the main pathophysiology of allergic diseases. It is closely related to the progression and severity of the disease. Oxidative stress and inflammation play a central role in acute liver damage caused by toxic compounds. The inflammatory response is associated with an increase in the number of eosinophils, mucus secretion and increased production of cytokines [13].

Current treatments to relieve allergic inflammation can only alleviate disease symptoms. It is important to investigate the pharmacology of this disease to produce an alternative solution to these treatments [14]. Many plants and plant extract compounds have been studied for AR treatment, but the efficacy and safety of these compounds have not yet been established [15].

During the search for treatment, the AR model was created on experimental animals and the effects of some substances were investigated.

In the study by Wen et al. on rats, an AR model was created with OVA and then botox application was performed. While eosinophil increases, vascular dilation, congestion, edema, and hyperplasia in the serous glands of the nasal mucosa group were detected, botox administration has been reported to significantly reduce these changes [16].

Intranasal corticosteroids form the basis of AR treatment. They act by reducing the flow of inflammatory cells and by inhibiting the release of cytokines (IL-1, IL-2, IL3, IL-6, INF- $\gamma$ , GM-CSF, TNF- $\alpha$ ), thereby reducing inflammation of the nasal mucosa. However, considering the side effects on different tissues, safer and more effective agents are needed [17].

The liver is the main metabolic organ in the body. It acts as an important hormonal gland and functions to maintain hormone balance and homeostasis. Steroid hormones regulate various biological pathways, mostly in the reproductive system and many metabolic processes. Liver and steroid hormones together contribute significantly to the maintenance of homeostasis and stress response [18].

Minshall et al. in their study evaluated the effect of MF used in the treatment of 69 patients with perennial AR on the histopathological features of the nasal mucosa, they did not find atrophic changes and local side effects in the nasal mucosa. They did not observe any changes in epithelial thickness, goblet cell distribution and density, morphological characteristics of the vessels and glands in the lamina propria, and basement membrane integrity. However, they found that the prevalence of inflammatory cells, particularly eosinophils, and mast cells, decreased [19].

In this study, intensive sinusoidal dilatation was found in the group in which AR was formed according to the G1 (C) group. In addition, swelling and moderate hydropic degeneration were observed in hepatocytes (Figures 2 and 3, Table 1).

Studies have shown that MF does not cause DNA damage in rat

liver cells, and it was stated that MF is not genotoxic.

The phenolic compounds contained in the olive tree (*Olea europaea*) have been found to be associated with a reduced risk of many chronic diseases, including phenolic acids, phenolic alcohols, flavonoids and secoiridoids, cardiovascular diseases and cancer. Oleuropein and its metabolite hydroxytyrosol exhibit various pharmacological properties, including potent antioxidant, antiatherogenic, anti-inflammatory, antiviral and anticancer effects. The liver is the main target organ for oxidative stress, and several experimental studies have provided strong evidence that oleuropein has beneficial hepatoprotective effect [20]. Olive oil and leaf extract have various health benefits. In a study, the effect of fluoxetine on the liver of rats was examined and the protective effects of olive leaf extract were evaluated [21].

In another study, the protective effect of Oleuropein against CCL4-induced liver damage was investigated and a significant reduction in liver inflammation was found after treatment with oleuropein [22].

MF has been reported to be a potent inhibitor of in vitro production of inflammatory cytokines IL-1, IL-6 and TNF- $\alpha$  [23]. In our study, there was a significant increase in TNF- $\alpha$  and IL-1  $\beta$  gene expression levels in AR group (G2) compared to other groups. TNF- $\alpha$  and IL-1 $\beta$  gene expression levels were significantly decreased in the G4 (AR+MF) compared to other groups ( $p < 0.000$ ). MF and oleuropein in the included group (G6); TNF- $\alpha$  and IL-1 $\beta$  gene expression levels were decreased compared to G1(C) and G4 (AR+MF) (Figure 1).

Oleuropein has also been reported to have protective effects against non-alcoholic fatty liver disease (NAFLD) in vivo [20].

In a study similar to our study, oleuropein has been reported to reduce the expression of a number of hepatic genes involved in oxidative stress responses and lipid peroxidation products and detoxification of proinflammatory cytokine genes [24]. Co-administration of olive oil and olive leaf extract has been reported to significantly reduce circulating liver function enzymes and proinflammatory cytokines and prevent fluoxetine-induced histological changes [24].

In our study, it was observed that G4 (AR+MF), G5 (AR+OLE) and G6 (AR+MF+OLE) tissue samples decreased significantly in the sinusoidal dilation areas compared to G2 (AR). The microscopic image of G5 (AR+OLE) was similar to that of the G1 (C) ( $p < 0.000$ ) (Figure 2).

As a result, comprehensive research on allergy and therapeutic mechanisms to combat allergic diseases offers new strategies to create effective treatments. Although intranasal corticosteroids are the most effective treatment in AR treatment, non-pharmacological treatments can also be used as a supplement to the current treatment. The data indicated that the application of oleuropein has no any detected side effects in the experimental AR model, as an auxiliary agent to MF. It can be suggested that the use of oleuropein in AR treatment will not cause any pathology especially in terms of liver. However, more comprehensive experimental models are needed to provide more detailed information.

**Scientific Responsibility Statement**

The authors declare that they are responsible for the article's scientific content including study design, data collection, analysis and interpretation, writing, some of the main line, or all of the preparation and scientific review of the contents and approval of the final version of the article.

**Animal and human rights statement**

All procedures performed in this study were in accordance with the ethical standards of the institutional and/or national research committee and with the 1964 Helsinki declaration and its later amendments or comparable ethical standards. No animal or human studies were carried out by the authors for this article.

**Funding:** None

**Conflict of interest**

None of the authors received any type of financial support that could be considered potential conflict of interest regarding the manuscript or its submission.

**References**

- Peters-Golden M, Gleason M, Toghiani A. Cysteinyl leukotrienes: multi-functional mediators in allergic rhinitis. *Clin Exp Allergy*. 2006; 36(6):689-703.
- Nagai H, Teramachi H, Tsuchiya T. Recent advances in the development of anti-allergic drugs. *Allergol Int*. 2006;55(1):35-42.
- Karaman M. Alerjik Hastalıklarda Fare Sıçan Modelleri (Mouse Rat Models in Allergic Diseases). *Klinik Tıp Pediatri Dergisi/ Journal of Clinical Medicine Pediatrics*. 2017; 9(2):186-93.
- Bakir M, Geyikoglu F, Koc K, Cerig S. Therapeutic effects of oleuropein on cisplatin-induced pancreas injury in rats. *J Cancer Res Ther*. 2018;14(3):671-78.
- Bousquet J, Schunemann J, Fonseca J, Samolinsk B, Bachert C, Canonica W, et al. MACVIA-ARIA Sentinel Network for allergic rhinitis (MASK-rhinitis): the new generation guideline implementation. *Allergy*. 2015;70(11):1372-92.
- Bayar N, Önerci M. Alerjik Rinitin Topikal Medikal Tedavisi (Topical Medical Treatment of Allergic Rhinitis). *K.B.B. ve Baş Boyun Cerrahisi Dergisi/ Journal of Ear Nose Throat and Head Neck Surgery*. 1994; 1(4): 272-6.
- Carr W. New therapeutic options for allergic rhinitis: back to the future with intranasal corticosteroid aerosols. *Am J Rhinol Allergy*. 2013;27(4):309-13.
- Muriel P, Rivera-Espinoza Y. Beneficial drugs for liver diseases. *J Appl Toxicol*. 2008;28(2):93-103.
- Drenth P, Van Uum H, Van Deuren M. Endurance run increased circulating IL-6 and IL-1 $\alpha$  but down-regulates ex vivo TNF- $\alpha$  and IL-1 $\beta$  production. *J Appl Physiol*. 1995;79(5):1497-503.
- Essayan M, Fox C, Levi-Schaffer F, Alam R, Rosenwasser J. Biologic activities of IL-1 and its role in human disease. *J Allergy Clin Immunol*. 1998;102(3):344-50.
- Sagıt M, Polat H, Gurgun G, Berk E, Gule S, Yasar M. Effectiveness of quercetin in an experimental rat model of allergic rhinitis. *Eur Arch Otorhinolaryngol*. 2017;274(8):3087-3095.
- Günel C, Demirci B, Meteöglü İ, Yılmaz M, Ömürlü K, Kocatürk T. The anti-inflammatory effects of thymoquinone in a rat model of allergic rhinitis. *J Ear Nose Throat*. 2017;27(5):226-32.
- Khan Q, Nafees S, Sultana S. Perillyl alcohol protects against ethanol induced acute liver injury in Wistar rats by inhibiting oxidative stress, NF- $\kappa$ B activation and proinflammatory cytokine production. *Toxicology*. 2011;279(1-3):108-14.
- Kim Y, Shin H, Park R, Kim W, Kim W. Comparison of antiallergic effects of pneumococcal conjugate vaccine and pneumococcal polysaccharide vaccine in a murine model of allergic rhinitis. *Laryngoscope*. 2013;123(10):2371-7.
- Schapoval A. Randomised controlled trial of butterbur and cetirizine for treating seasonal allergic rhinitis. *BMJ*. 2002;324(7330):144-7.
- Wen D, Yuan F, Wang L, Hou P. Botulinum toxin therapy in the ovalbumin-sensitized rat. *Neuroimmunomodulation*. 2007;14(2):78-83.
- Braido F, Lagasio C, Piroddi G, Baiardini I, Canonica W. New treatment options in allergic rhinitis: patient considerations and the role of ciclesonide. *Ther Clin Risk Manag*. 2008;4(2):353-61.
- Charni-Natan M, Aloni-Grinstein R, Oshe E, Rotter V. Liver and Steroid Hormones-Can a Touch of p53 Make a Difference? *Front Endocrinol*. 2019;10:374
- Minshall E, Ghaffar O, Cameron L, O'Brien F, Quinn H, Rowe-Jones J. Assessment by nasal biopsy of long-term use of mometasone furoate aqueous 48 nasal spray (Nasonex) in the treatment of perennial rhinitis. *Otolaryngol Head Neck Surg*. 1998; 118(5):648-54.
- Park S, Choi Y, Um J, Yoon K, Park T. Oleuropein attenuates hepatic steatosis induced by high-fat diet in mice. *J Hepatol*. 2011;54(5):984-93.
- Elgebaly A, Mosa M, Allach M, El-massry F, El-Ghorab H, Al Hroob M, et al. Olive oil and leaf extract prevent fluoxetine-induced hepatotoxicity by attenuating oxidative stress, inflammation and apoptosis. *Biomed Pharmacother*. 2018;98:446-53.
- Domitrović R, Jakovac H, Marchesi V, Šain I, Romić Ž, Rahelić D. Preventive and therapeutic effects of oleuropein against carbon tetrachloride-induced liver damage in mice. *Pharmacol Res*. 2012;65(4):451-64.
- Barton E, Jakway P, Smith R, Siegel I. Cytokine inhibition by a novel steroid, mometasone furoate. *Immunopharmacol Immunotoxicol*. 1991;13(3):251-61.
- Kim Y, Choi Y, Park T. Hepatoprotective effect of oleuropein in mice: mechanisms uncovered by gene expression profiling. *Biotechnol J*. 2010;5(9):950-60.

**How to cite this article:**

Özlem Öztopuz, Özlem Coşkun, Başak Büyük. The effect of Oleuropein on liver in experimental allergic rhinitis model. *Ann Clin Anal Med* 2020;11(Suppl 1): S61-66